

**LETTER TO THE EDITOR****To THE EDITOR****An Unusual Todd's Phenomenon: Post-Ictal Prosopagnosia**

**Keywords:** Prosopagnosia, Nonconvulsive status epilepticus, Cavernous malformation

Prosopagnosia, colloquially referred to as “face blindness”, is the inability to recognize individual faces in the presence of otherwise normal visual and cognitive domains. Classically, neuroimaging and autopsy findings have been used to define the anatomical basis of facial recognition and prosopagnosia.<sup>1</sup> Bilateral lesions of the occipitotemporal zone were first identified as the responsible region, however, it is now recognized that prosopagnosia can arise as a result of unilateral damage, predominantly on the right.<sup>1,2</sup> Specific areas of the inferior occipital and fusiform gyri termed the occipital face area (OFA) and fusiform face area (FFA) have been implicated as key regions for facial recognition.<sup>2</sup>

Most patients studied have either congenital prosopagnosia or acquired prosopagnosia from lesions such as tumor or stroke.<sup>2</sup> One case reported acquired prosopagnosia after a prolonged period of status epilepticus, suggesting the probable sensitivity of these areas to any structural damage.<sup>3</sup> There have been rare case reports describing transient prosopagnosia as a result of structural or metabolic disease. Ictal prosopagnosia, however, is exceedingly rare. A single case report from 1978 describes a patient with ictal prosopagnosia that resolved with surgical resection of a congenital (atrophic) lesion in the left temporal-occipital area.<sup>4</sup>

We present a 71-year-old right-handed man referred to neurology for visual disturbances. His history was significant for a known right temporo-occipital cavernous malformation that was felt to have caused two episodes of bilateral tonic-clonic seizures 7 years before. He was treated with lamotrigine and had been seizure free until his new acute presentation.

One week prior to his presentation, he began experiencing a positive visual phenomenon. He noted flashing lights, associated with nausea and headache. A visual assessment by his optometrist was normal. Over the next 7 days, he developed more complex visual hallucinations including seeing additional cars on the road and floating, disembodied faces. He presented to the local emergency department where he had two bilateral tonic-clonic seizures. His lamotrigine was increased and he was sent home. The following day, however, he noticed difficulty seeing objects in his left field of vision and when his wife entered the room, he was unable to recognize her until she spoke. He immediately returned to the emergency department where he was referred to neurology. There were no factors identified to account for the recurrent seizures, including no acute findings on CT and no clinical or biochemical evidence of infection. A lamotrigine level was not drawn, but there were no concerns regarding patient compliance.

His neurologic exam was unremarkable with the exception of a partial left homonymous hemianopsia. The patient demonstrated ongoing intermittent prosopagnosia both for new faces, and for the faces of his wife and sister. An EEG was obtained during which the patient experienced ongoing visual hallucinations. This corresponded to multiple electrographic seizures associated with

his ability to describe continuously appearing faces in his left visual field (Figure 1A–C).

With the addition of clobazam and levetiracetam, the patient had reduced frequency but not the resolution of his visual symptoms. A repeat EEG showed improvement from the previous, but with ongoing frequent electrographic and clinical events characterized by hallucinations of faces. Following episodes of face hallucinations, he continued to experience intermittent prosopagnosia; there was no EEG captured during these periods. Perampanel was added to his other seizure medications. A repeat MRI showed no acute findings and no change in the appearance of the right temporo-occipital cavernous malformation (Figure 2A).

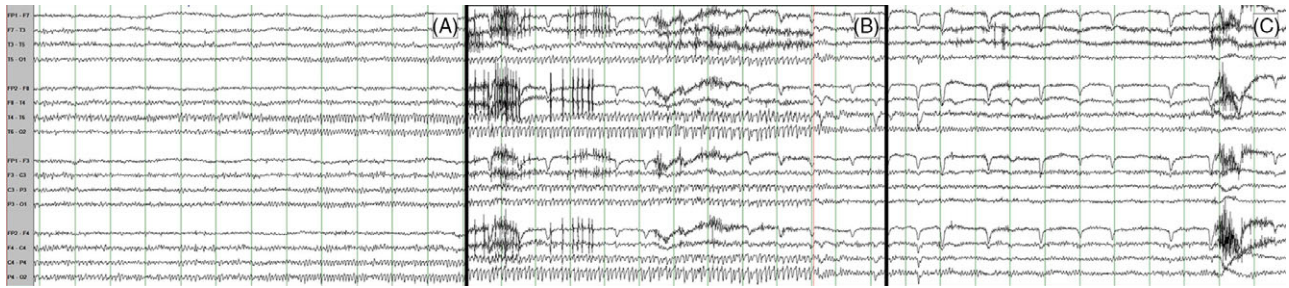
Approximately 2 weeks after admission, with medications failing to control his seizures, the patient underwent a right craniotomy for resection of the cavernous malformation (Figure 2B). In the first 48 h following surgery, he had infrequent visual hallucinations which then ceased. He remained seizure free on levetiracetam and lamotrigine and has remained so at his 1-year follow-up assessment. Goldmann visual field testing revealed no residual visual field deficit. He has had no further hallucinations or residual prosopagnosia.

This case is only the second reported case of peri-ictal prosopagnosia. The clinical presentation, in our case, is not surprising from a neuroanatomical perspective. This patient had a cavernous malformation at the right temporo-occipital junction. While the lesion was slightly lateral to the fusiform gyrus, its proximity to both the OFA and FFA in the context of his ictal phenomena supports the activation of these areas.

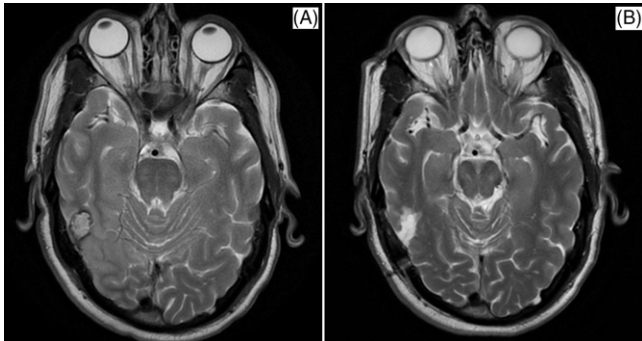
A consideration in this case is whether the prosopagnosia was in fact ictal, or rather, a post-ictal Todd's phenomenon. We suggest that the location of the cavernous malformation caused ictal activation of not only more elementary visual networks as evidenced by his “simple” visual hallucinations, but also of the facial recognition network as evidenced by his frequent hallucinations of faces followed by periods of concurrent prosopagnosia and visual field deficit. We hypothesize that frequent ictal activation of the FFA resulted in the near-constant hallucinations of faces appearing in his left visual field and that the prosopagnosia was a post-ictal phenomenon causing suppression of this area, resulting in the impairment of facial recognition between seizures. The complete resolution of both the visual hallucinations and the prosopagnosia following resection of the cavernous malformation supports this hypothesis.

To conclude, we report a case of nonconvulsive status epilepticus characterized by unusual visual phenomena, including marked prosopagnosia, secondary to a right temporo-occipital cavernous malformation. This is, to our knowledge, the second described case of prosopagnosia as a peri-ictal phenomenon, and the first case of prosopagnosia as a probable Todd's phenomenon.

While our patient's seizures had a partial response to multi-drug therapy, he ultimately required complete surgical resection of the causative lesion for definitive treatment. He had complete resolution of his various ictal phenomenon postoperatively and remains seizure free.



**Figure 1:** Bipolar montage EEG. Sensitivity=5 microvolts/mm, high-frequency filter=70 Hz, low-frequency filter=0.3 Hz. (A) Onset of ictal rhythm seen best in T4–T6. (B) Progression of ictal rhythm to involve the contralateral side (T5–O1). (C) Resolution of ictal rhythm.



**Figure 2:** (A) Axial T2-weighted MRI shows a right temporal cavernous measuring  $1.8 \times 1.3 \times 1.3$  cm. (B) Axial T2-weighted MRI showing total resection of cavernous malformation (right).

#### DISCLOSURES

The authors report no conflicts of interest pertaining to the content of this article.

#### STATEMENT OF AUTHORSHIP

RG was involved in conceptualization, literature review, drafting, and editing of the manuscript.

MS was involved in conceptualization and editing, and conducted collection and interpretation of electroencephalogram data.

DC was involved in conceptualization and editing of the manuscript.

#### STATEMENT OF INFORMED CONSENT

Informed signed consent for publication was provided by the patient.

Rebecca S. George  
Division of Neurology, Department of Medicine, Dalhousie University, Halifax, Nova Scotia Canada

R. Mark Sadler  
Division of Neurology, Department of Medicine, Dalhousie University, Halifax, Nova Scotia Canada

David B. Clarke  
Division of Neurosurgery, Department of Surgery, Dalhousie University, Halifax, Nova Scotia, Canada

Correspondence to: Dr. Rebecca S. George, Department of Neurology, Dalhousie University/Queen Elizabeth II Health Sciences Centre, Halifax Infirmary – Suite 3822, 1796 Summer Street, Halifax, NS B3H3A7, Canada. Email: [rb565338@dal.ca](mailto:rb565338@dal.ca)

#### REFERENCES

1. Barton JJ. Structure and function in acquired prosopagnosia: lessons from a series of 10 patients with brain damage. *J Neuropsychol.* 2008;2:197–225.
2. Corrow SL, Dalrymple KA, Barton JJ. Prosopagnosia: current perspectives. *Eye Brain.* 2016;8:165–75.
3. Wright H, Wardlaw J, Young AW, Zeman A. Prosopagnosia following nonconvulsive status epilepticus associated with a left fusiform gyrus malformation. *Epilepsy Behav.* 2006;9:197–203.
4. Agnetti V, Carreras M, Pinna L, Rosati G. Ictal prosopagnosia and epileptogenic damage of the dominant hemisphere. A case history. *Cortex.* 1978;14:50–7.